A Review of Smoking-Related Interstitial Fibrosis, Respiratory Bronchiolitis, and Desquamative Interstitial Pneumonia

Overlapping Histology and Confusing Terminology

Kristine E. Konopka, MD; Jeffrey L. Myers, MD

• Smoking-related lung diseases traverse a spectrum of clinicopathologic entities, with cases often comprising a complex mixture of findings. The complexity of the diagnostic process extends beyond the histologic findings to the nomenclature, which is murky from a seemingly unending expansion of terms being applied to a handful of pathologic changes. Here, we focus our review on smoking-related interstitial fibrosis, respiratory bronchiolitis, and desquamative interstitial pneumonia, 3 entities that perhaps show the most histologic overlap and suffer from competing terminology.

(*Arch Pathol Lab Med*. 2018;142:1177–1181; doi: 10.5858/arpa.2018-0240-RA)

Smoking-related lung pathology represents a histologically and clinically diverse spectrum, ranging from the acute presentation of eosinophilic pneumonia seen in the context of bolus-type exposures[1] to those affiliated with chronic progressive loss of function and malignancy. In a time of evolving modes of tobacco delivery, such as vaping, new pulmonary manifestations of smoking are also being recognized, including exogenous lipoid pneumonia.[2]

Although some of these entities are morphologically distinct, the histologic manifestations of smoking are rarely seen in isolation, and many pathologic diagnoses share overlapping features. At times, a biopsy may show a complex combination of smoking-related findings for which separating the clinically meaningful from the incidental becomes an exhausting task. Additionally, given the prevalence of tobacco use, the histologic findings related to smoking are more often a distractor, serving only to corroborate a patient's reported social history rather than to establish a clinically relevant diagnosis. Therefore, the pathologist's role in recognition of smoking-related lesions includes understanding the clinical context in which the histologic findings may be clinically impactful.

The challenges surrounding accurate and meaningful diagnosis of smoking-related lung pathology are compounded by confusing terminology, in part because of shuffling of nomenclature and renaming of histologic entities. Selection of preferred terms should be partly institution based, using wording familiar to your clinicians. However, we also encourage that pathologic diagnoses convey information about possible therapies and anticipated prognosis, avoiding "wastebasket" terms to the extent possible.

Here, we focus on 3 histologic diagnoses that represent common problems in our thoracic consult practice: smoking-related interstitial fibrosis (SRIF), respiratory bronchiolitis (RB), and desquamative interstitial pneumonia (DIP). The goals of this review are to summarize the salient histologic features and anticipated clinical settings, an approach for differentiating these lesions from their mimics, and our rationale for preferred naming.

SMOKING-RELATED INTERSTITIAL FIBROSIS

The term *SRIF* was first coined by Dr Anna-Luise Katzenstein et al[3] in 2010 to describe a relatively common fibrotic lesion seen exclusively in current or former smokers. Smoking-related interstitial fibrosis has been referred to using a variety of other terms, including *RB with fibrosis*,[4] *RB-associated interstitial lung disease (RBILD) with fibrosis*,[5] and *airspace enlargement with fibrosis*.[6] Because these entities are histologically synonymous, nomenclature becomes a matter of preference. We prefer SRIF to distinguish it from RB, and although airspace enlargement with fibrosis is descriptively accurate, it does not reference smoking, which is an association worth highlighting.

Smoking-related interstitial fibrosis is most commonly encountered in upper lobe sections as an incidental finding in current or former smokers undergoing lung wedge biopsy or lobectomy for other reasons.[3,6] Yousem[5] described the same phenomenon, referring to it as RBILD with fibrosis, in patients originally diagnosed with nonspecific interstitial pneumonia (NSIP), suggesting that in a subset of patients

Accepted for publication May 9, 2018.

From the Department of Pathology, University of Michigan, Ann Arbor.

The authors have no relevant financial interest in the products or companies described in this article.

Presented in part at the New Frontiers in Pathology meeting; October 19–21, 2017; Ann Arbor, Michigan.

Corresponding author: Kristine E. Konopka, MD, Department of Pathology, University of Michigan, 1500 E Medical Center Dr, 2G332 UH, Ann Arbor, MI 48109 (email: krkonopk@med.umich.edu).

Downloaded from https://aplm.kglmeridian.com at 2026-03-06 via free access

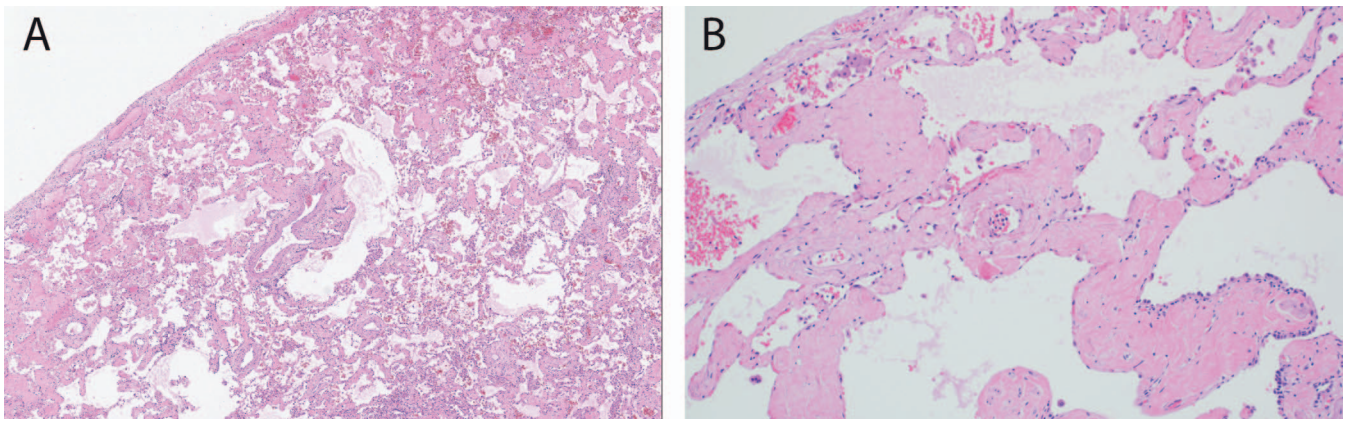

Figure 1. *Smoking-related interstitial fibrosis is characterized by expansion of the subpleural interstitium by nondistorting, paucicellular, ropy collagen (hematoxylin-eosin, original magnifications ×40 [A] and ×100 [B]).*

SRIF may account for a syndrome of mild restrictive lung disease. On high-resolution computed tomography of the chest, SRIF is most frequently described as upper lobe–predominant reticulations with or without ground-glass opacities, and is invariably accompanied by emphysema.[4]

Histologically, SRIF is characterized by alveolar septal thickening by a distinctive pattern of paucicellular, dense, eosinophilic collagen that has a ropy or waxy quality, and is accompanied by emphysematous changes and RB (discussed below). Hypertrophic smooth muscle bundles may accompany the fibrosis and at times predominate.[7] The fibrosis is limited to the subpleural and peribronchiolar interstitium, not rising to the level of a diffuse chronic interstitial pneumonia. Although SRIF is associated with varying degrees of airspace enlargement, the lung architecture is relatively preserved without significant architectural distortion in the form of scarring or honeycomb change (Figure 1, A and B).[3]

Pulmonary function tests have been reported in only a few patients and have shown preserved lung volumes with reduced forced expiratory volume in 1 second and a disproportionate reduction in diffusing capacity of the lungs for carbon monoxide. Additionally, with rare exceptions, patients discovered to have SRIF do not suffer from progressive interstitial lung disease. For these reasons, SRIF is generally regarded as having no special clinical consequence in most patients, for whom it serves only to corroborate a smoking history.[3–5] Given its negligible clinical significance, the importance of recognizing SRIF as a distinct histologic entity is therefore to avoid confusion with more serious fibrotic chronic interstitial pneumonias, namely usual interstitial pneumonia (UIP) and the fibrotic variant of NSIP.

Although SRIF is morphologically distinct, separating SRIF from UIP and NSIP can be difficult on small biopsies and may require incorporation of ancillary data. Both SRIF and UIP have a subpleural distribution; however, SRIF shows a predilection for the upper lobes, whereas UIP is commonly characterized as having predominantly lower lobe involvement, with the additional radiographic findings of traction bronchiectasis and honeycomb change. Smoking-related interstitial fibrosis should not show architectural distortion due to scarring or lung remodeling in the form of microscopic honeycomb change, both of which are histologic features of UIP.[8] Although rare fibroblastic foci can occasionally be identified in SRIF, their presence should raise concern for UIP and prompt careful review of any available clinical and radiologic data to assess for the presence of clinically significant diffuse interstitial lung disease.[3] Finally, clinical features that would be unusual for a diagnosis of SRIF alone include complaints of progressively worsening exertional dyspnea and cough. In those cases, SRIF might be accompanying UIP; therefore, sampling may be critical to reaching a definitive diagnosis.[6]

Distinguishing SRIF and NSIP can be even more challenging, and upon retrospective review, some cases diagnosed as NSIP have later been recategorized as SRIF.[5] Smoking-related interstitial fibrosis should show distinct, abrupt zonation without bridging fibrosis and should never rise to the level of a diffuse fibrotic chronic interstitial pneumonia. Confluent fibrosis that is neither exquisitely subpleural nor peribronchiolar favors a diagnosis of NSIP. Although peribronchiolar lymphoid aggregates may be seen in SRIF, significant interstitial inflammation is not a feature, and is a finding that can be helpful in establishing the diagnosis of a chronic interstitial pneumonia, such as NSIP. Like UIP, patients with NSIP typically present with respiratory complaints of progressive dyspnea with predominantly lower lobe involvement on imaging studies, both features that are in sharp contrast to the typically clinically occult, upper lobe-predominant presentation of SRIF.[7,9]

RESPIRATORY BRONCHIOLITIS

Respiratory bronchiolitis was first described as a manifestation of smoking in 1974 by Dr Dennis Niewoehner et al,[10] who characterized the lesion as the accumulation of lightly pigmented macrophages within the lumens of distal airways and peribronchiolar airspaces (Figure 2). This is often accompanied by mild thickening of the peribronchiolar interstitium by fibrosis and a minimal chronic inflammatory infiltrate.

Respiratory bronchiolitis is a histologic marker of smoking status and can be identified in virtually all actively smoking individuals. Respiratory bronchiolitis is present in approximately half of ex-smokers, with the changes persisting many years after smoking cessation. Rarely, it can be seen in reported nonsmokers who have significant exposure to secondhand smoke or other environmental insults.[10,11] Respiratory bronchiolitis is usually of little clinical consequence and is discovered incidentally in patients undergoing

Downloaded from https://aplm.kglmeridian.com at 2026-03-06 via free access

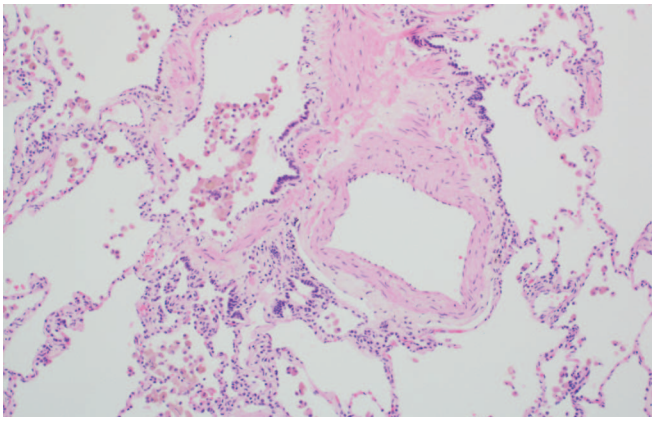

Figure 2. *Respiratory bronchiolitis is appreciated as clusters of lightly pigmented macrophages within the lumen of a terminal airway and peribronchiolar airspaces (hematoxylin-eosin, original magnification ×100).*

lung wedge biopsy to evaluate for other forms of lung disease.[11]

In a subset of patients, however, RB is the only pathologic finding and seems to account for clinical interstitial lung disease with common presenting complaints of cough and exertional dyspnea. Such patients are frequently characterized as having a mild to moderate restrictive ventilatory defect on pulmonary function tests, usually with impaired diffusion capacity, and diffuse changes on chest imaging that are described as ground-glass or centrilobular nodules.[12–14] In these cases, the diagnosis of RBILD may be applicable.[12]

In patients with RBILD, smoking cessation is a mainstay of therapy, and frequently results in stabilization or resolution of symptoms. Even patients who continue to smoke usually experience a relatively stable clinical course, with no deaths attributable to a diagnosis of RBILD alone. The role of oral corticosteroids is controversial, with only rare patients experiencing transient improvement.[13,14]

It is worth reemphasizing that RBILD is histologically indistinguishable from incidental RB, and a diagnosis of RBILD relies on incorporation of clinical and radiologic data. Because a diagnosis of RBILD is contingent upon excluding other forms of diffuse lung disease, this diagnosis should not be made on transbronchial biopsy alone and is instead reserved for wedge biopsies.

One of the main challenges in the diagnosis of RB is separating smoker's pigment from hemosiderin, the latter occurring most commonly in the settings of diffuse alveolar hemorrhage or chronic passive congestion due to heart failure (Figure 3, A and B). Smoker's pigment is usually yellow and finely granular, but it can become coarser with heavy, long-term tobacco use, making the distinction from hemosiderin difficult.[11] An iron stain, such as Prussian blue, highlights both hemosiderin and smoker's pigment, so application of tissue special stains may not be helpful in differentiating the two.[12] An iron stain, however, can sometimes be useful in that smoker's pigment tends to be finely granular and pale staining as opposed to the darkly staining, coarse granules more typical of bleeding-related hemosiderin. Iron stains may also be useful in highlighting iron encrustation of vascular elastica, a finding that occurs in the settings of chronic hemorrhage or chronic passive congestion and is sometimes referred to as endogenous pneumoconiosis.

DESQUAMATIVE INTERSTITIAL PNEUMONIA

Desquamative interstitial pneumonia was originally described in 1965 by Dr Averill Liebow et al,[15] who elegantly detailed the histologic findings and clinical features of 18 patients with this condition. In this original publication, the authors described diffuse, massive filling of airspaces by what we now know to be macrophages,[16] and variable degrees of affiliated, relatively uniform-appearing interstitial fibrosis. The primary goal in introducing DIP as a diagnostic entity was to separate this group from those patients who had historically been lumped into UIP.[15] The combined early works of Liebow et al,[15] Gaensler et al,[17] and Carrington et al[18] successfully demonstrated DIP as a distinct clinical entity with superior outcomes as compared with patients with UIP.

The association between DIP and smoking was recognized many years after its initial descriptions, with only a small subset of patients reporting themselves as nonsmokers and no other significant exposure history.[19] There is significant clinical overlap between DIP and RBILD, with both patient populations similarly presenting with exertional dyspnea, cough, and diffuse ground-glass opacities on chest imaging studies; however, the degree of physiologic

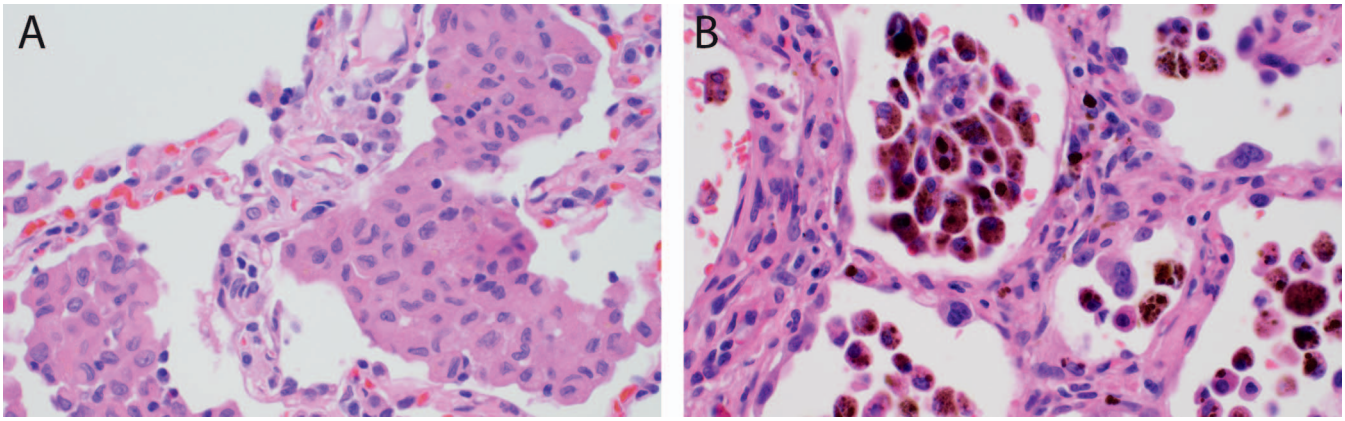

Figure 3. *Smoker's pigment (A) is yellow and finely granular, contrasting with hemosiderin pigment (B), which is coarser and golden brown. Smoker's pigment may resemble hemosiderin with heavy tobacco use, making the distinction difficult (not pictured) (hematoxylin-eosin, original magnification ×400).*

Downloaded from https://aplm.kglmeridian.com at 2026-03-06 via free access

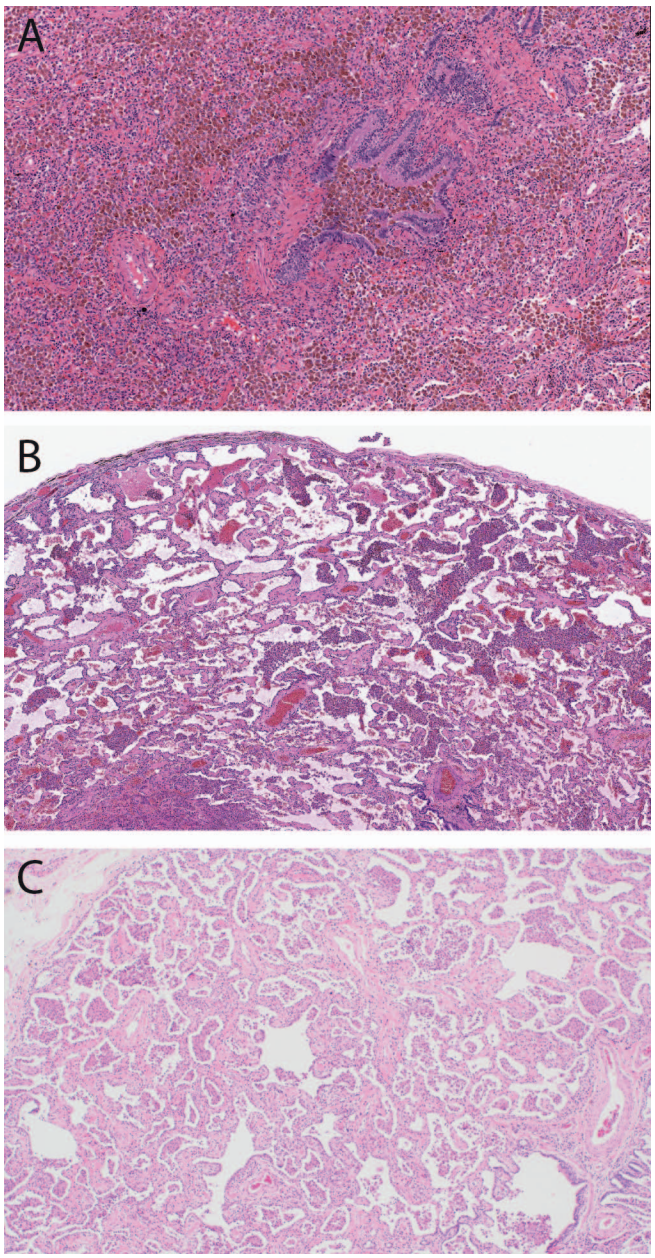

Figure 4. *Desquamative interstitial pneumonia is characterized by diffuse filling of airspaces by smoker's macrophages with variable degrees of fibrosis, ranging from (A) none to (B) smoking-related interstitial fibrosis–like and (C) diffuse (hematoxylin-eosin, original magnifications ×80 [A] and ×40 [B and C]).*

impairment tends to be worse in DIP, with those patients suffering from more severely reduced diffusing capacity of the lungs for carbon monoxide. Furthermore, like RBILD patients, most DIP patients experience a stable clinical course, with some reported improvement upon quitting smoking. Data supporting the use of oral corticosteroids are weak, but immunomodulatory therapy is usually attempted with the hope of mitigating clinical progression. In contrast to RBILD, some patients with DIP suffer from progressive deterioration in lung function, culminating in death.[13,20] Nonetheless, overall survival is significantly better than for patients with UIP.[17,18] Desquamative interstitial pneumonia is characterized by diffuse accumulation of macrophages within distal airspaces, which theoretically contrasts with RB, where macrophages are limited to the peribronchiolar airspaces. Desquamative interstitial pneumonia may also be accompanied by varying degrees of interstitial fibrosis (Figure 4, A through C).[15] In some cases, there is no significant interstitial fibrosis, whereas in others, fibrosis is limited to the peribronchiolar interstitium and subpleural lung zones in a manner that is synonymous with SRIF. Other times, however, interstitial fibrosis becomes diffuse, rising to the level of a chronic interstitial pneumonia with changes resembling fibrotic NSIP. In cases of fibrotic DIP, it is perhaps most important to exclude UIP with prominent DIP-like changes, a finding not infrequently encountered in smokers with UIP, in whom this finding has no special significance beyond corroborating a smoking history.[8] Significant architectural distortion in the forms of scarring and microscopic honeycomb change should not be seen in DIP, and favors a diagnosis of UIP with DIP-like features.

In the setting of no or minimal interstitial fibrosis, the distinction between DIP and RB can be readily made at the extreme ends of the spectrum. However, these changes exist along a continuum, and not infrequently, the cellular intra-alveolar exudate spills beyond the immediate peribronchiolar region but does not reach the subjective threshold of "diffuse." In this setting, given the significant histologic and clinical overlap between DIP and RBILD, the distinction may be arbitrary. Some have proposed dispensing of the dueling terminology altogether and collapsing these 2 entities under a single pathologic diagnosis of RBILD. In this model, the term DIP is completely eliminated, and cases with diffuse fibrosis would be categorized as fibrotic NSIP, whereas SRIF would suffice for those in which the fibrosis has histologic features previously described for this condition. Acknowledging the overlapping features, in our own practice, we continue to try to separate DIP from RBILD, mentioning SRIF as a secondary finding when present and reserving fibrotic NSIP for never smokers with changes resembling DIP.

Some have argued that fibrotic NSIP is more appropriate terminology for DIP cases in which diffuse fibrosis is a conspicuous feature. In some respects, the controversy surrounding the distinction of DIP from fibrotic NSIP is unimportant, with limited clinical consequence. The proposal to categorize all cases as fibrotic NSIP is driven, in part, by observations that lesions resembling fibrotic DIP have been described in nonsmokers, including individuals with other significant exposure histories and patients with systemic connective tissue disease.[21] In our practice, we continue to apply a diagnosis of DIP, albeit rarely in smokers, and distinguish it from SRIF based on the distribution and histologic characteristics of the concomitant fibrosis. In patients reporting themselves as never smokers, a diagnosis of fibrotic NSIP may be more appropriate. The rationale for the continued use of DIP in smokers is that NSIP gives no indication that smoking may be etiologic and therapeutically relevant for the patient, which a diagnosis of DIP implies. Having said that, we recognize that smoking cessation is a logical therapeutic strategy in any smoker with diffuse fibrotic lung disease regardless of the histologic subtype. In the end, the distinction between DIP and fibrotic NSIP is often arbitrary. It is perhaps most important to underscore that the patient has a smoking-related fibrotic lung disease that is not UIP.

Downloaded from https://aplm.kglmeridian.com at 2026-03-06 via free access

CONCLUSIONS

Smoking-related lung diseases represent a spectrum of intra-alveolar and interstitial changes that are highly overlapping and only reliably separable at the extremes. Many cases do not fit neatly into a specific category and diagnosis should be driven by synthesis of clinical, radiologic, and histologic findings.

References

1. Uchiyama H, Suda T, Nakamura Y, et al. Alterations in smoking habits are associated with acute eosinophilic pneumonia. *Chest*. 2008;133(5):1174–1180.
2. McCauley L, Markin C, Hosmer D. An unexpected consequence of electronic cigarette use. *Chest*. 2012;141(4):1110–1113.
3. Katzenstein AL, Mukhopadhay S, Zanardi C, Dexter E. Clinically occult interstitial fibrosis in smokers: classification and significance of a surprisingly common finding in lobectomy specimens. *Hum Pathol*. 2010;41(3):316–325.
4. Reddy TL, Mayo J, Churg A. Respiratory bronchiolitis with fibrosis: high resolution computed tomography findings and correlation with pathology. *Ann Am Thorac Soc*. 2013;10(6):590–601.
5. Yousem SA. Respiratory bronchiolitis-associated interstitial lung disease with fibrosis is a lesion distinct from fibrotic nonspecific interstitial pneumonia: a proposal. *Mod Pathol*. 2006;19(11):1474–1479.
6. Kawabata Y, Hoshi E, Murai K, et al. Smoking-related changes in the background lung specimens resected for lung cancer: a semiquantitative study with correlation to postoperative course. *Histopathology*. 2008;53(6):707–714.
7. Katzenstein AL. Smoking-related interstitial fibrosis (SRIF): pathologic findings and distinction from other chronic fibrosing lung diseases. *J Clin Pathol*. 2013;66(10):882–887.
8. Katzenstein AL, Zisman DA, Litzky LA, Nguyen BT, Kotloff RM. Usual interstitial pneumonia: histologic study of biopsy and explant specimens. *Am J Surg Pathol*. 2002;26(12):1567–1577.
9. Katzenstein AL, Fiorelli RF. Nonspecific interstitial pneumonia/fibrosis: histologic features and clinical significance. *Am J Surg Pathol*. 1994;18(2):136–147.
10. Niewoehner DE, Kleinerman J, Rice DB. Pathologic changes in the peripheral airways of young cigarette smokers. *N Engl J Med*. 1974;291(15):755–758.
11. Fraig M, Shreesha U, Savici D, Katzenstein AL. Respiratory bronchiolitis: a clinicopathologic study in current smokers, ex-smokers, and never smokers. *Am J Surg Pathol*. 2002;26(5):647–653.
12. Myers JL, Veal CF Jr, Shin MS, Katzenstein AL. Respiratory bronchiolitis causing interstitial lung disease: a clinicopathologic study of six cases. *Am Rev Respir Dis*. 1987;135(4):880–884.
13. Ryu, JH, Myers JL, Capizzi SA, Douglas WW, Vassallo R, Decker PA. Desquamative interstitial pneumonia and respiratory bronchiolitis-associated interstitial lung disease. *Chest*. 2005;127(1):178–184.
14. Portnoy J, Veraldi KL, Schwarz MI, et al. Respiratory bronchiolitis-interstitial lung disease: long-term outcome. *Chest*. 2007;131(3):664–671.
15. Liebow AA, Steer A, Billingsley JG. Desquamative interstitial pneumonia. *Am J Med*. 1965;39:369–404.
16. Valdivia E, Hensley G, Leory EP, Wu J, Jaeschke W. Morphology and pathogenesis of desquamative interstitial pneumonitis. *Thorax*. 1977;32(1):7–18.
17. Gaensler EA, Goff AM, Prowse CM. Desquamative interstitial pneumonia. *N Engl J Med*. 1966;274(3):113–128.
18. Carrington CB, Gaensler EA, Coutu RE, Fitzgerald MX, Gupta RG. Usual and desquamative interstitial pneumonia. *Chest*. 1976;69(2 suppl):261–263.
19. Yousem SA, Colby TV, Gaensler EA. Respiratory bronchiolitis-associated interstitial lung disease and its relationship to desquamative interstitial pneumonia. *Mayo Clin Proc*. 1989;64(11):1373–1380.
20. Craig PJ, Wells AU, Doffman S, et al. Desquamative interstitial pneumonia, respiratory bronchiolitis and their relationship to smoking. *Histopathology*. 2004;45(3):275–282.
21. Nicholson AG, Colby TV, Wells AU. Histopathological approach to patterns of interstitial pneumonia in patients with connective tissue disorders. *Sarcoidosis Vasc Diffuse Lung Dis*. 2002;19(1):10–17.

Downloaded from https://aplm.kglmeridian.com at 2026-03-06 via free access